INSTITUTS GUIRADO

Caso Clínico-Radiológico de Abril 2017
RM y CBCT

Jorge Salmerón

INSTITUTS GUIRADO

Paciente de 38 años de edad con antecedentes de parálisis facial de repetición. Dos episodios en 6 años. Sensación de inestabilidad , hipoacusia mixta y acúfenos pulsátiles.

INSTITUTS GUIRADO

RM Oídos

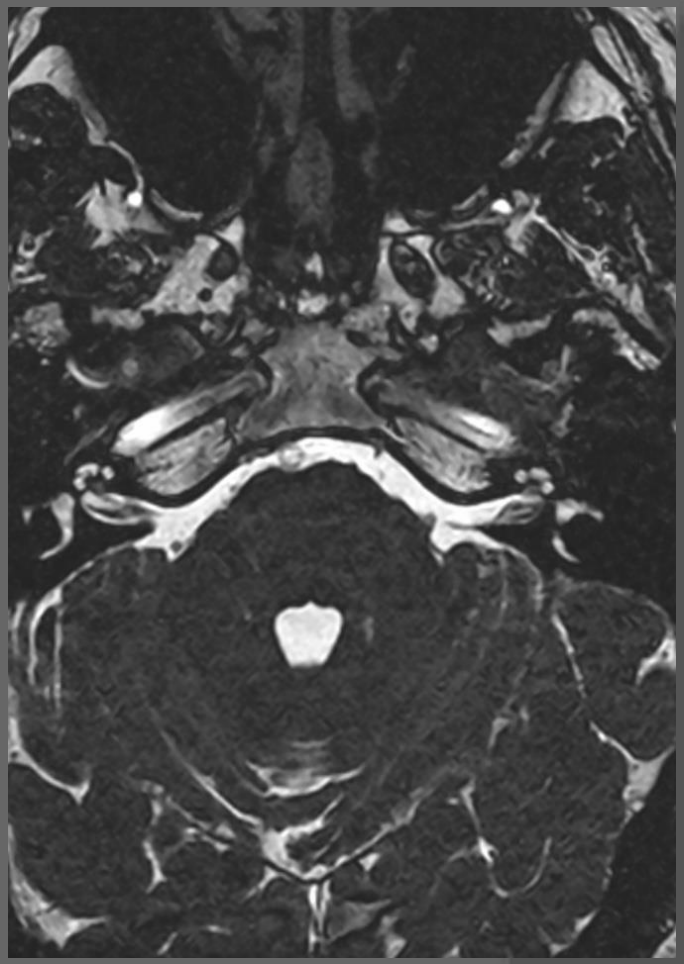

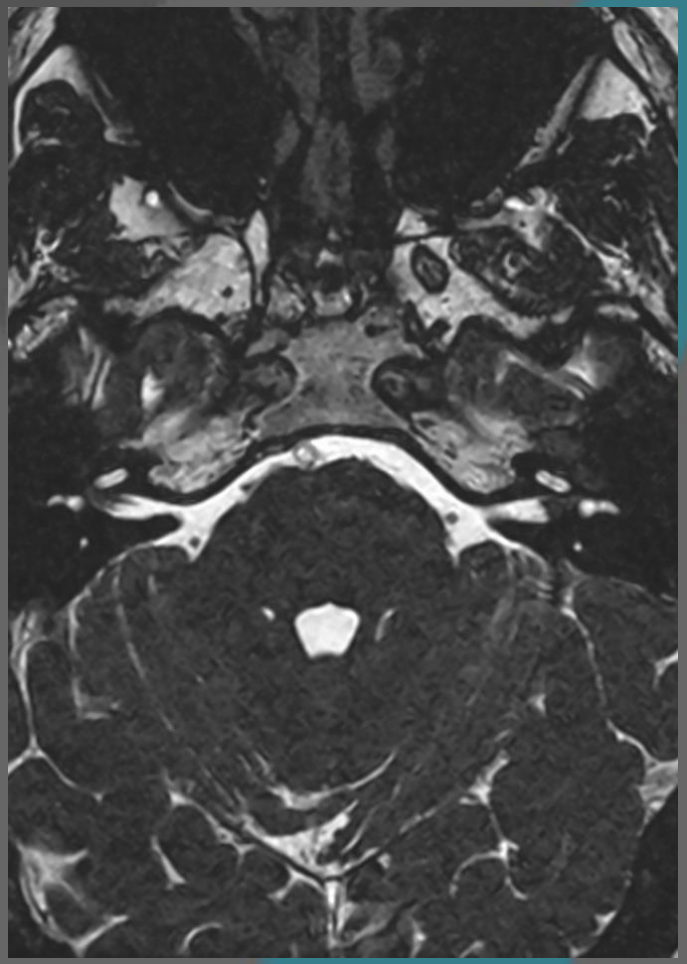

Cortes axiales FSE T2 Fiesta de ambos CAIs.

INSTITUTS GUIRADO

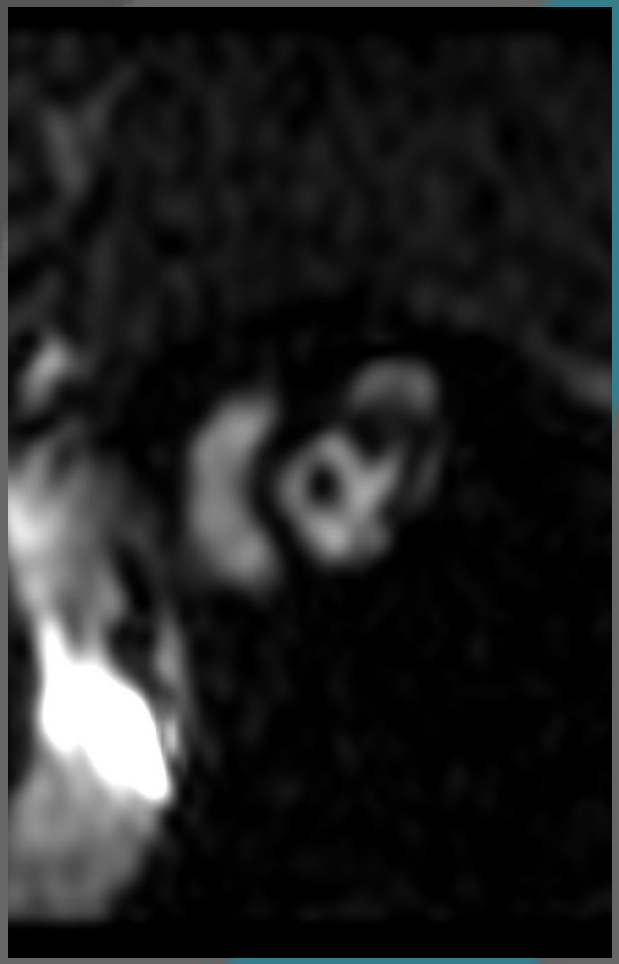

Cortes Sagitales Oblicuos del CAIs

INSTITUTS GUIRADO

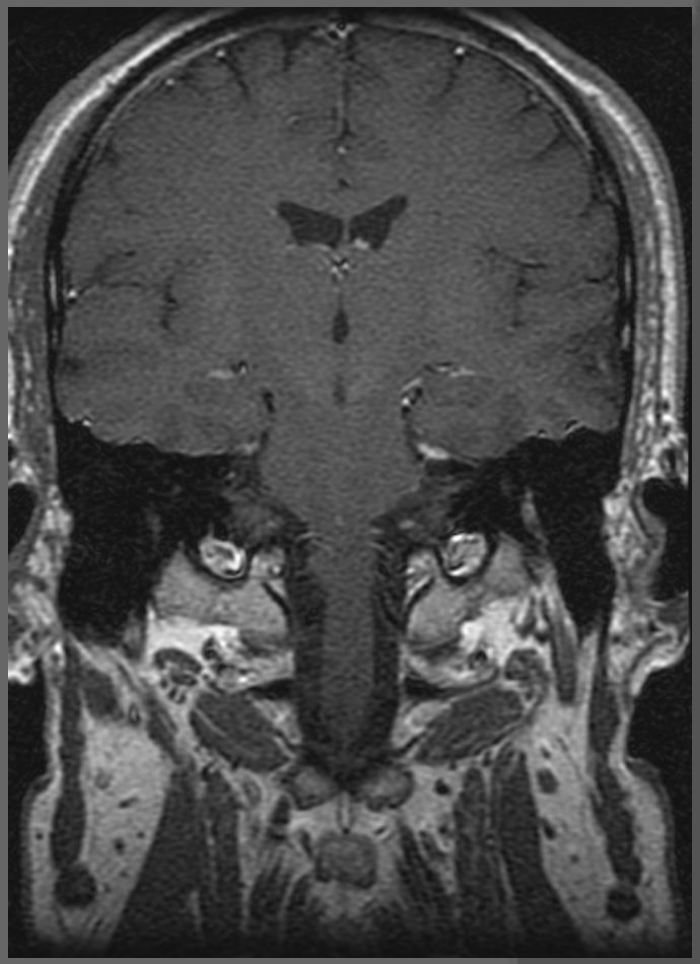

T1 con contraste

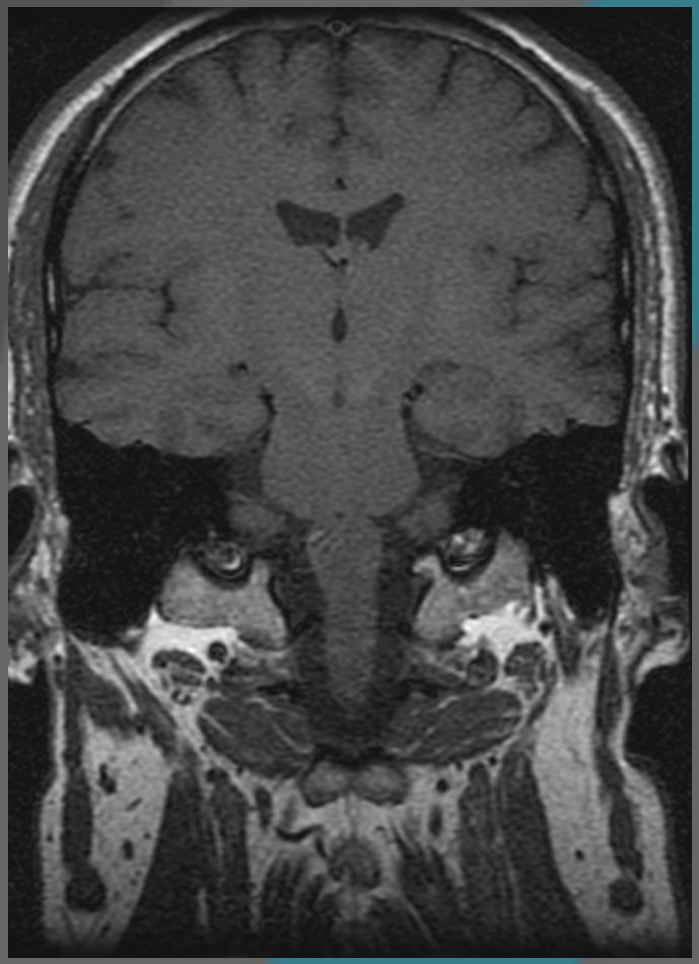

T1 sin contraste

INSTITUTS GUIRADO

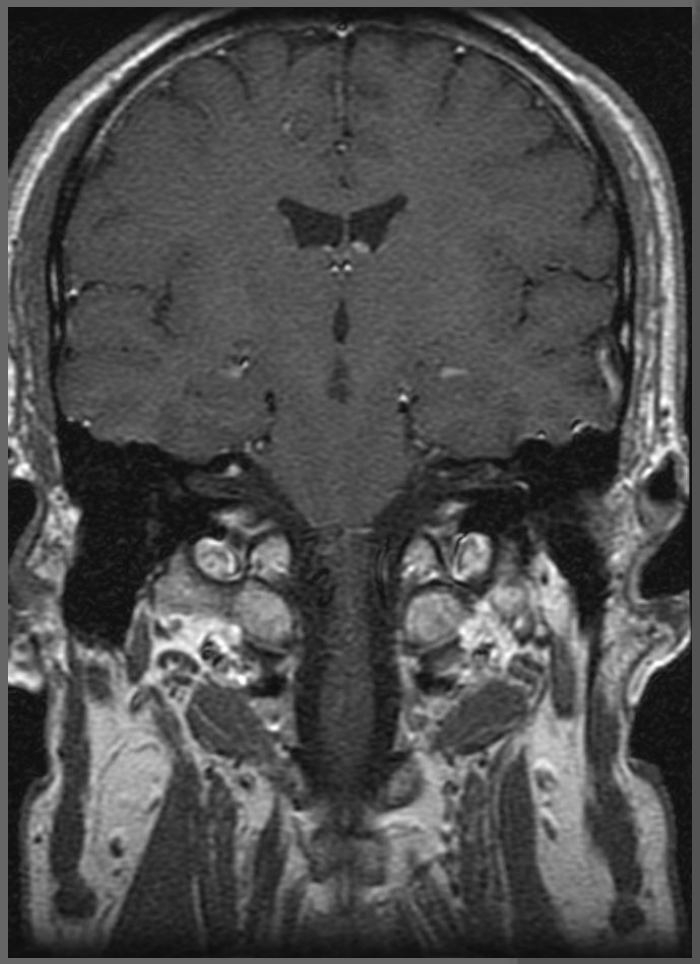

T1 con contraste

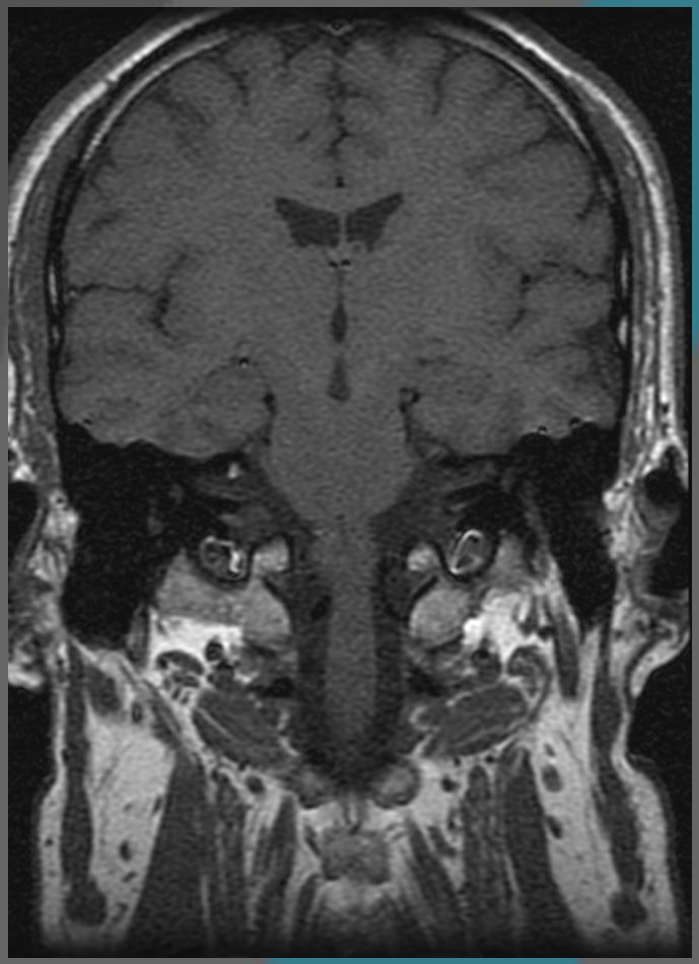

T1 sin contraste

INSTITUTS GUIRADO

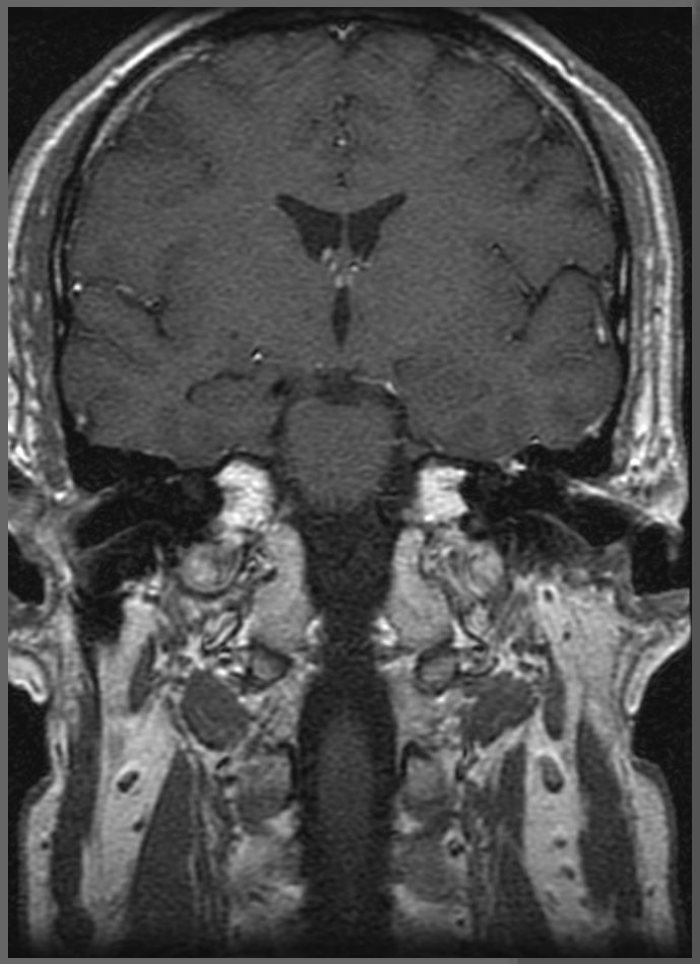

T1 con contraste

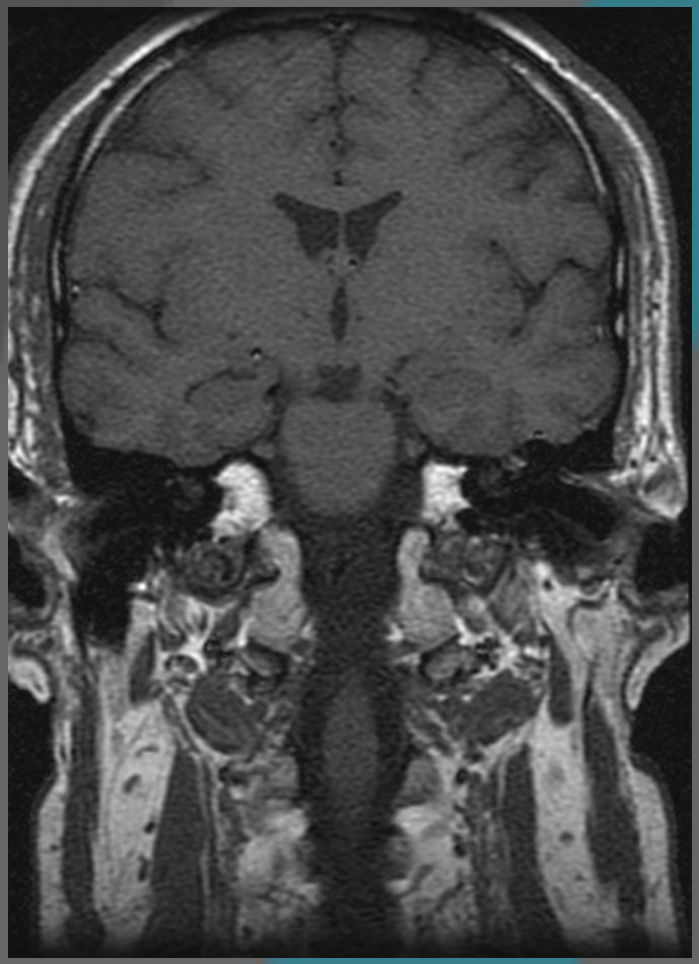

T1 sin contraste

INSTITUTS GUIRADO

CBCT Oídos

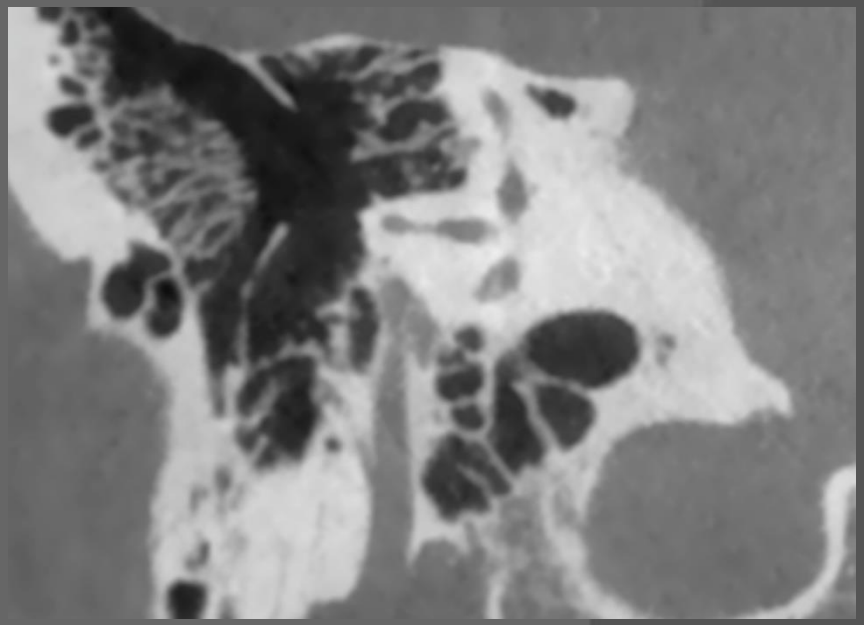

Derecho

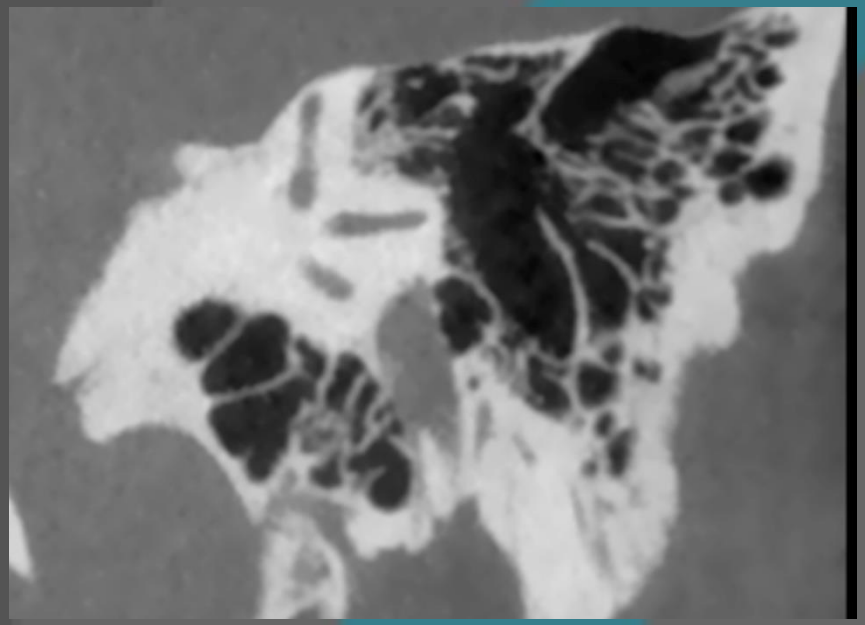

Izquierdo

INSTITUTS GUIRADO

CBCT Oídos

Derecho

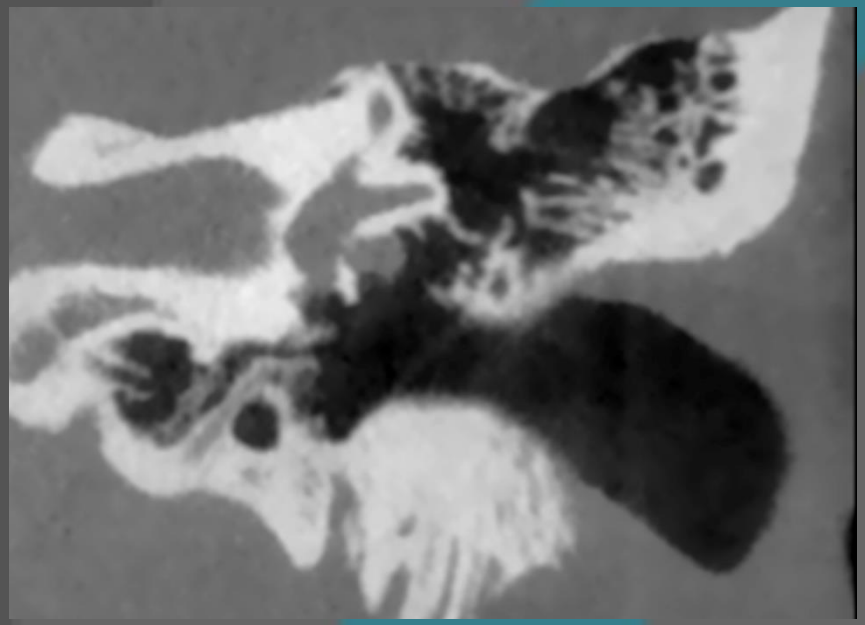

Izquierdo

INSTITUTS GUIRADO

CBCT Oídos

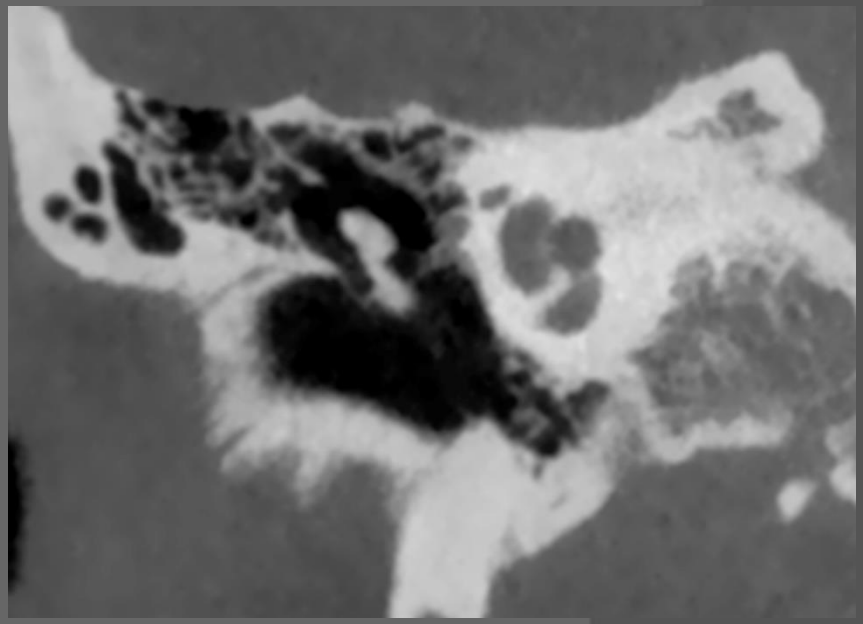

Derecho

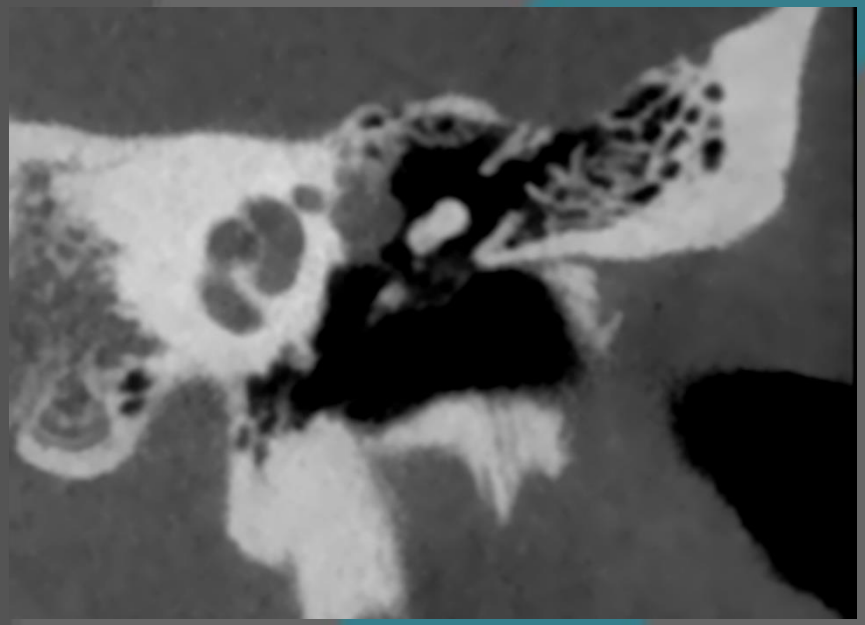

Izquierdo

CBCT Oídos

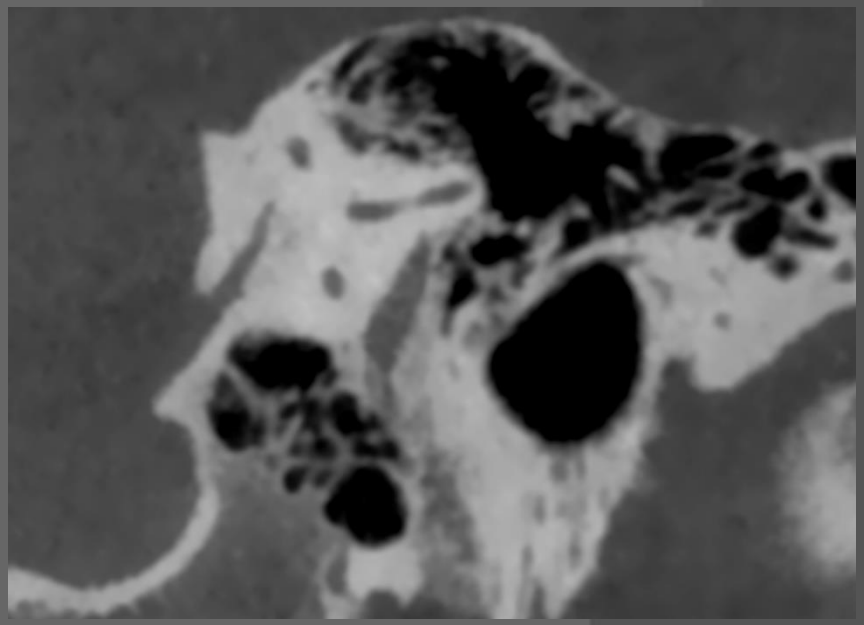

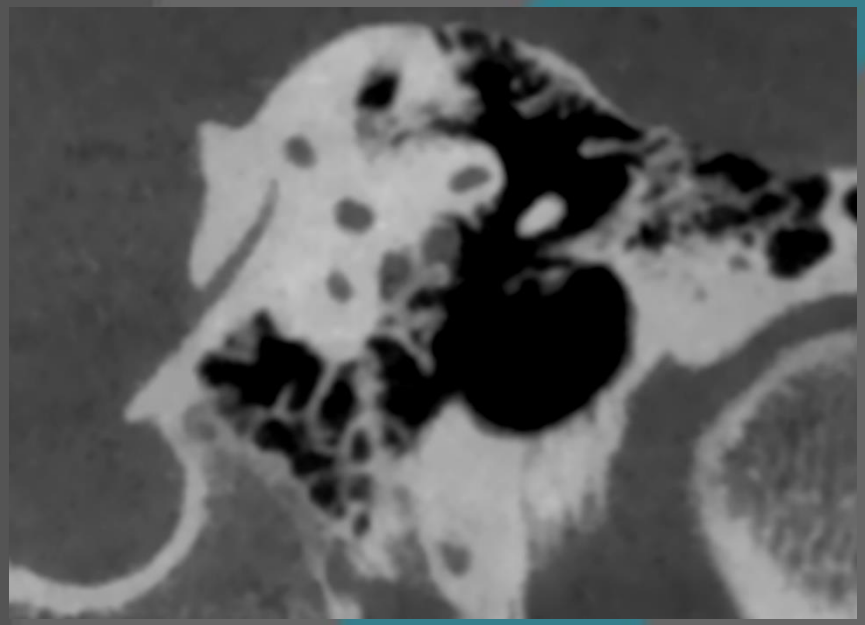

Izquierdo

CBCT Oídos

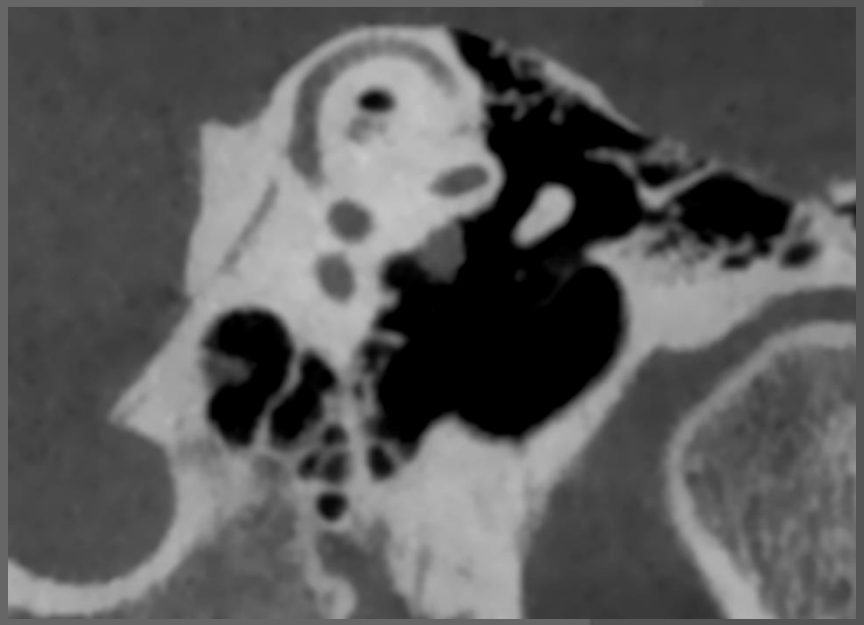

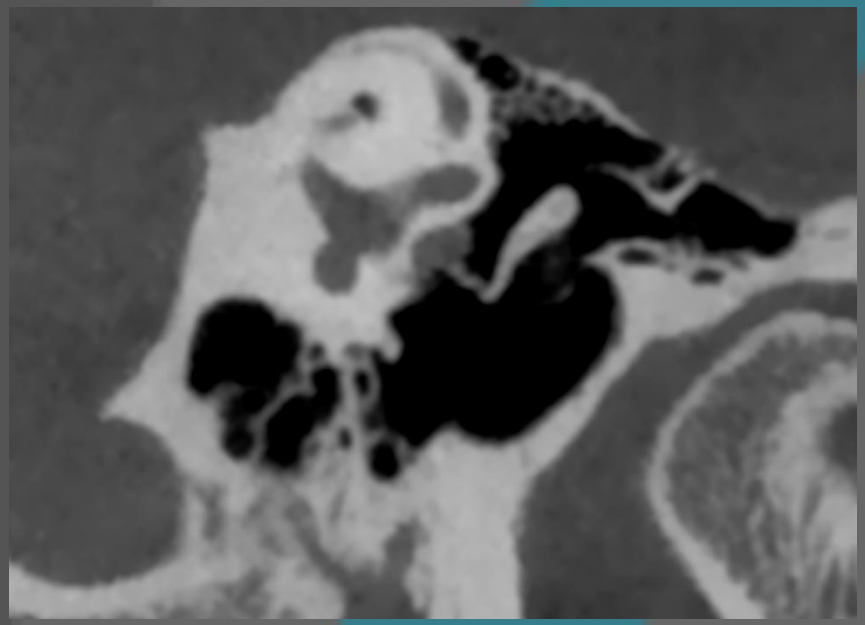

Izquierdo

INSTITUTS GUIRADO

CBCT Oídos

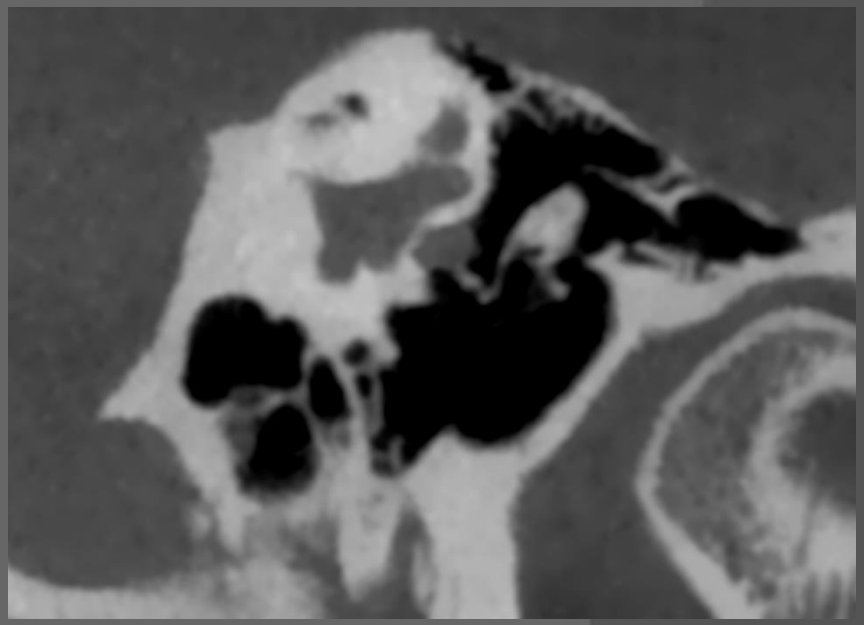

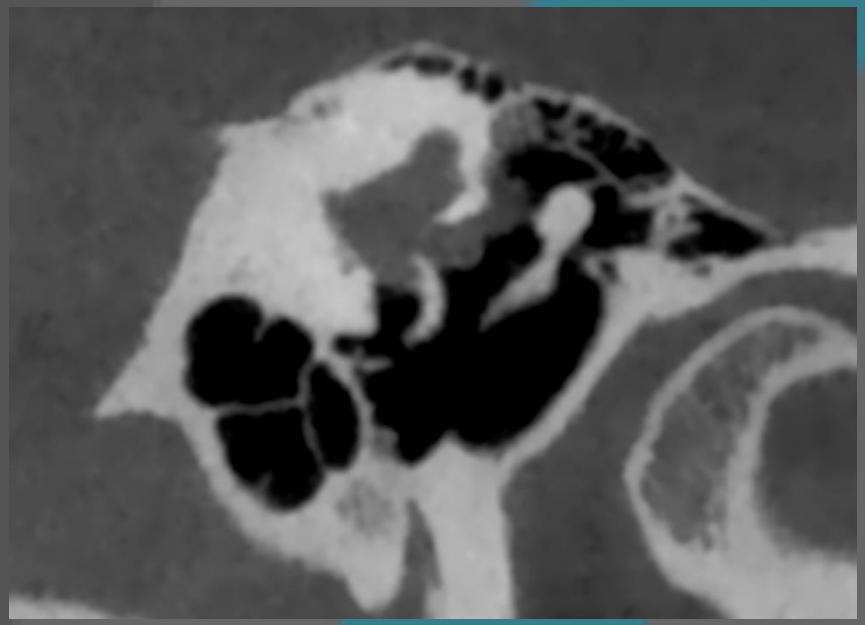

Izquierdo

INSTITUTS GUIRADO

CBCT Oídos

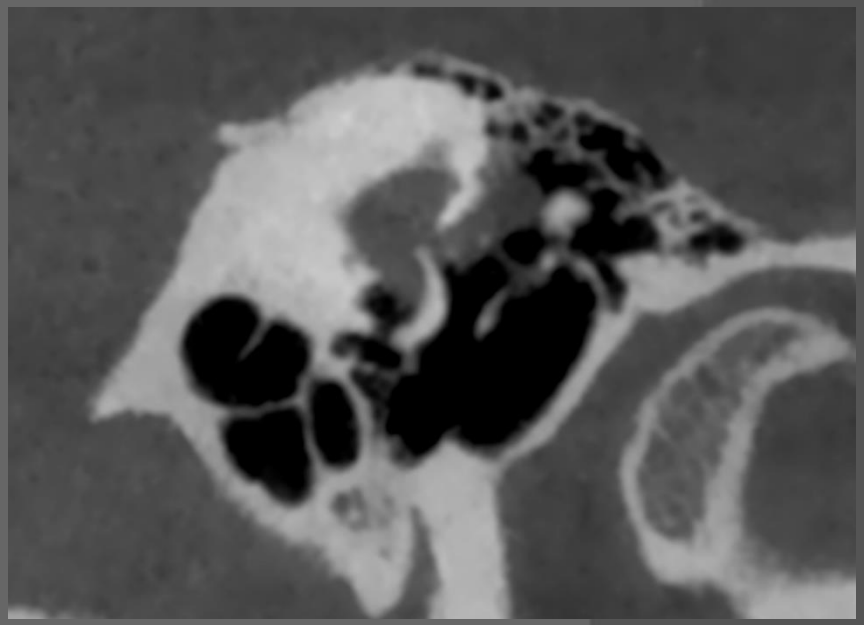

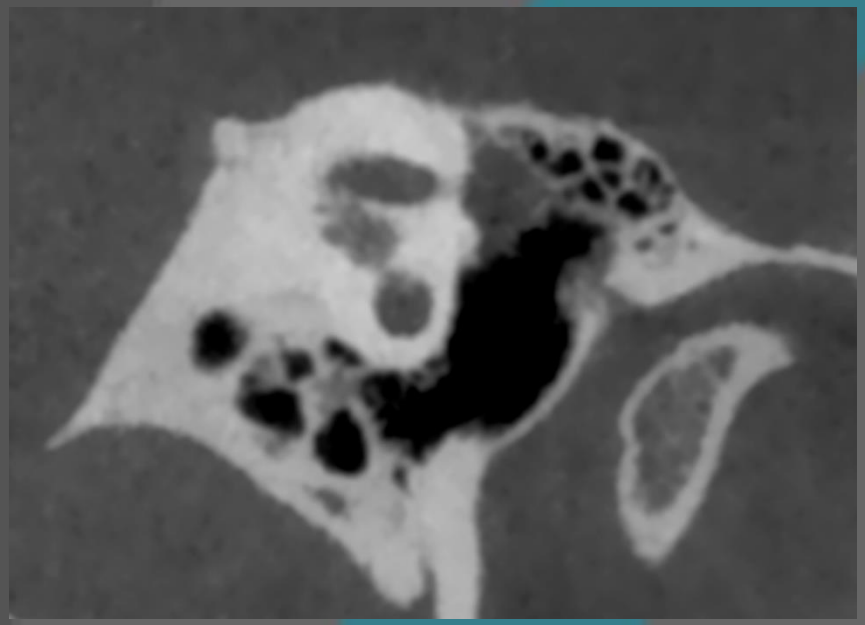

Izquierdo

Hallazgos RM:

En el estudio de RM de CAIs se aprecia una ocupación parcial del conducto.

En la reconstrucción sagital oblicua se aprecia como dicho proceso ocupa los límites anterosuperiores del conducto. Flecha amarilla

En las imágenes T1 sin y con contraste se demuestra una captación lineal anómala del medio de contraste en el trayecto del nervio facial, flechas rojas.

INSTITUTS GUIRADO

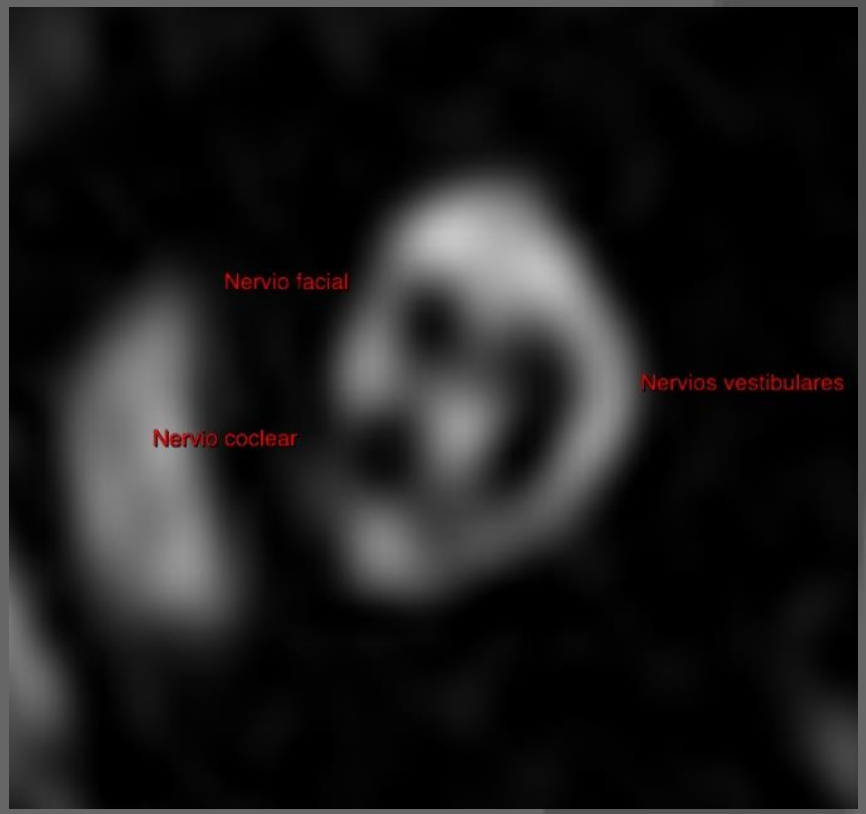

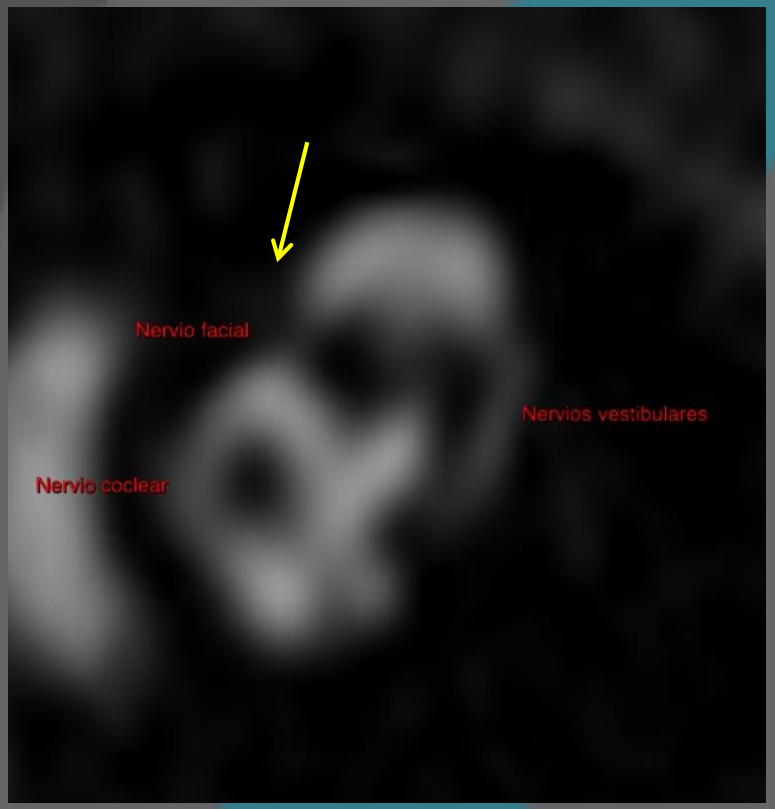

Proceso expansivo que ocupa los límites anteriorosuperiores del CAI

INSTITUTS GUIRADO

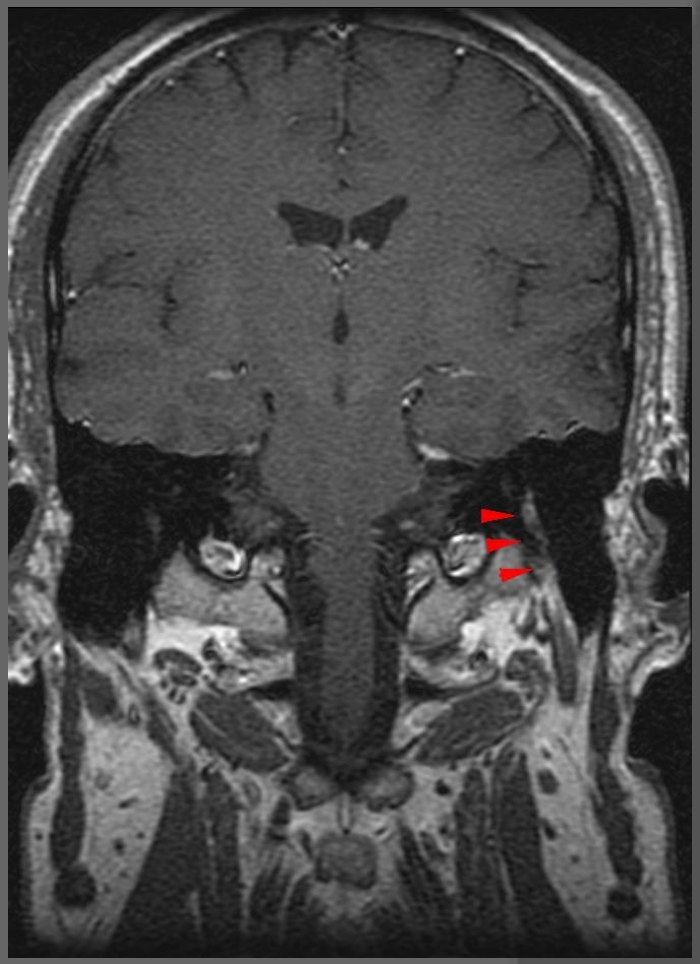

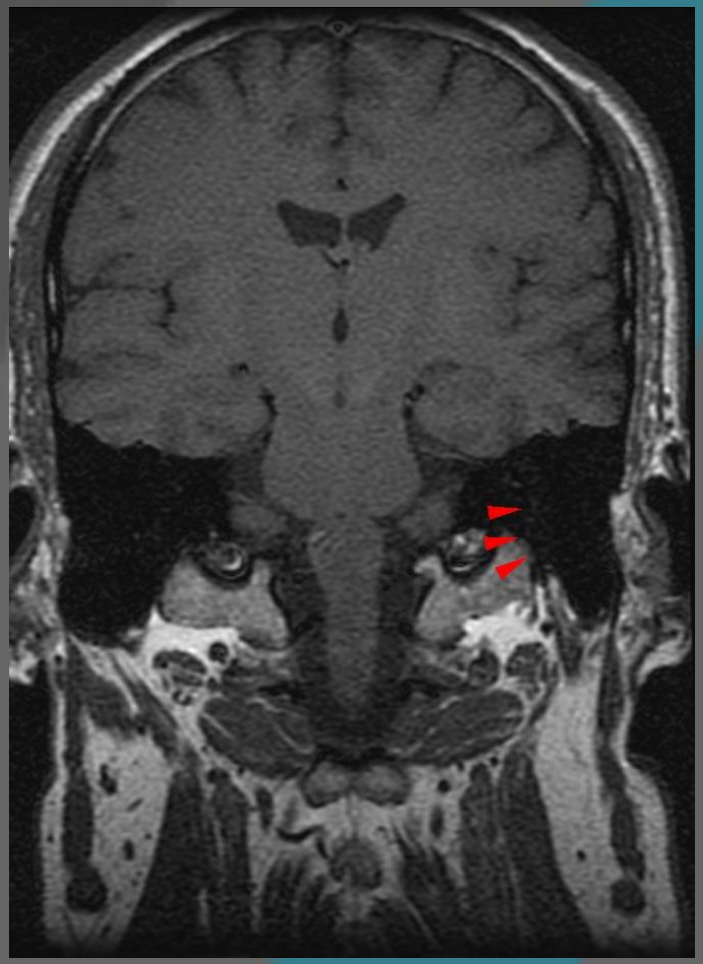

T1 con y sin contraste: Realce de la porción mastoidea del VII par

INSTITUTS GUIRADO

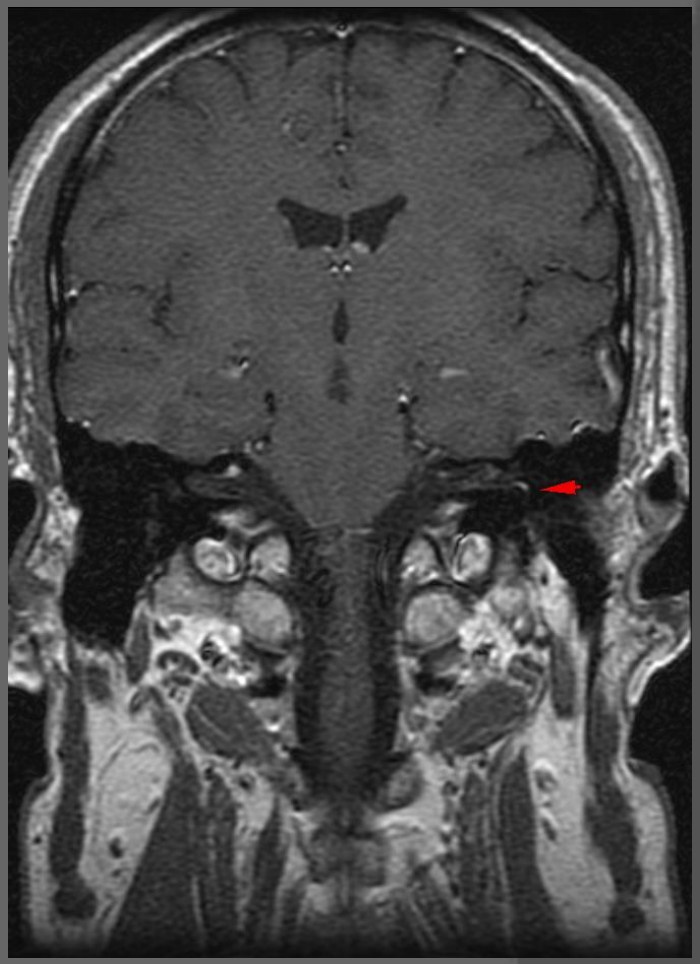

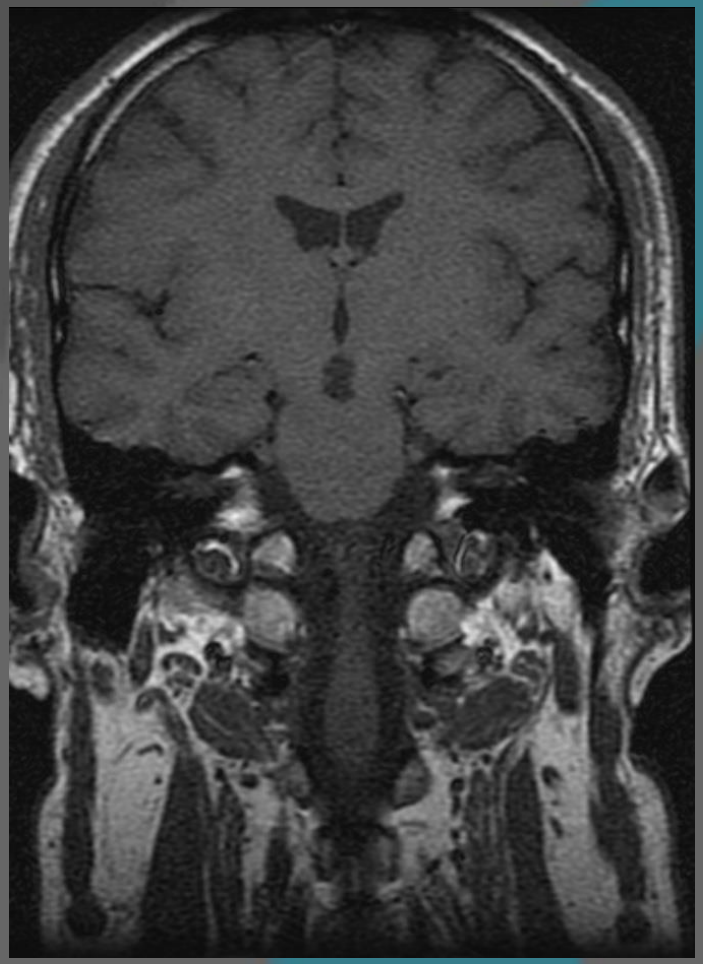

T1 con y sin contraste: Realce porción timpánica del VII par craneal izquierdo

INSTITUTS GUIRADO

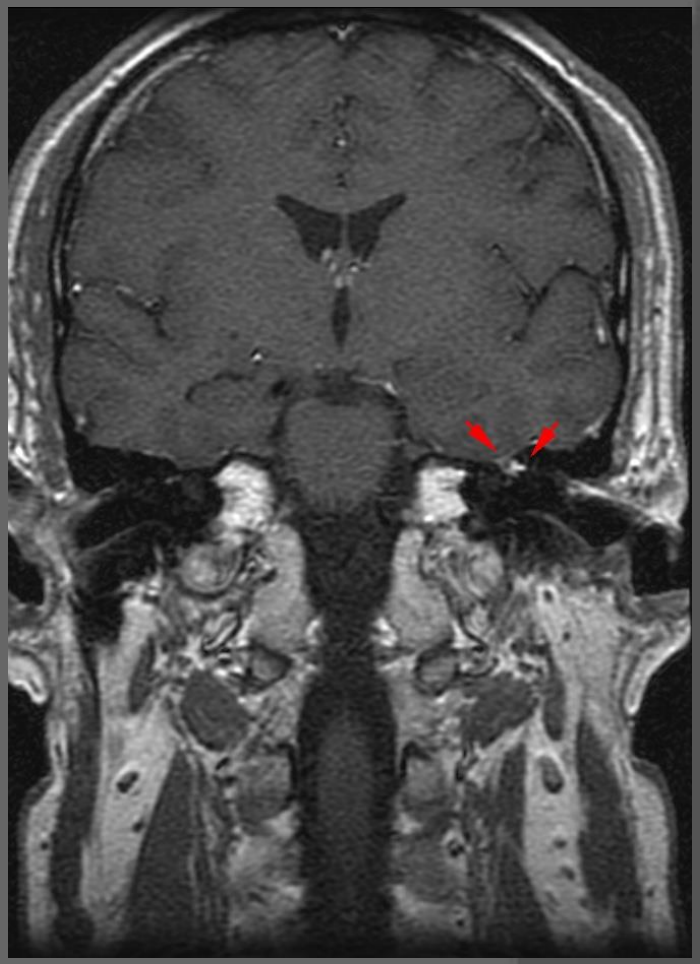

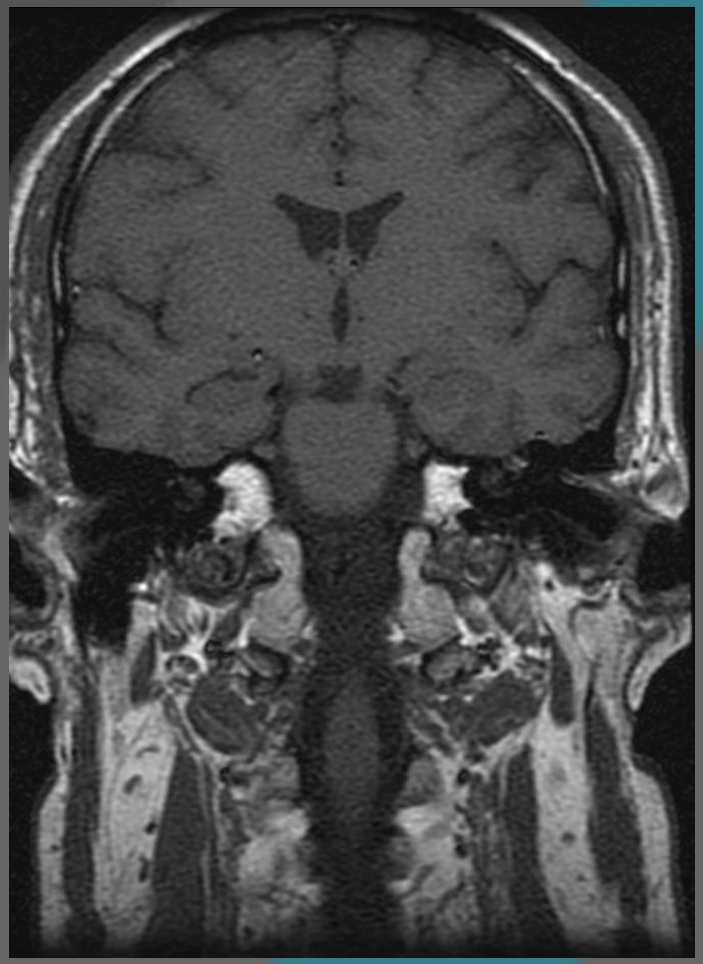

T1 con y sin contraste: Realce porción laberíntica del VII par craneal izquierdo

Hallazgos del CBCT

Se realiza estudio de tomografía computarizada con haz cónico, cortes de 0.150 mm de espesor y baja dosis 70 DLP mGy-cm para planificación quirúrgica y confirmación de los hallazgos.

Se confirma una remodelación del acueducto de Fallopio en su porción mastoidea, timpánica y laberíntica, flechas rojas, con dehiscencia parcial del canal óseo. La porción laberíntica del acueducto aparece remodelada/ensanchada, corte axial flecha roja.

INSTITUTS GUIRADO

CBCT Oídos

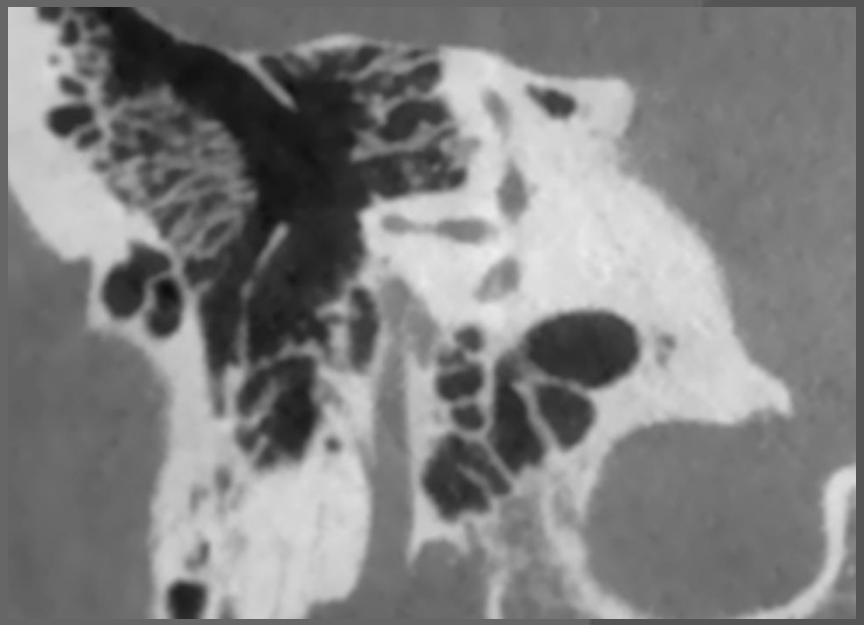

Derecho

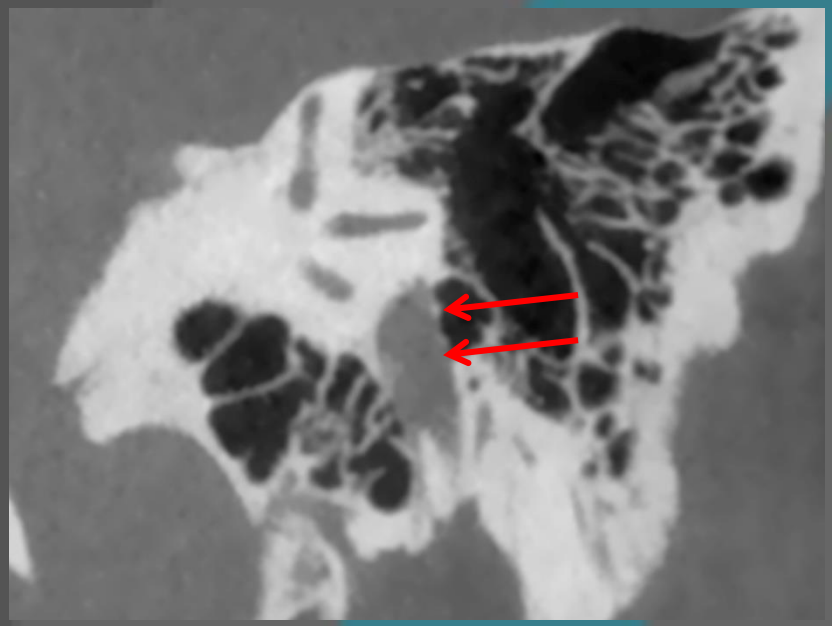

Izquierdo

INSTITUTS GUIRADO

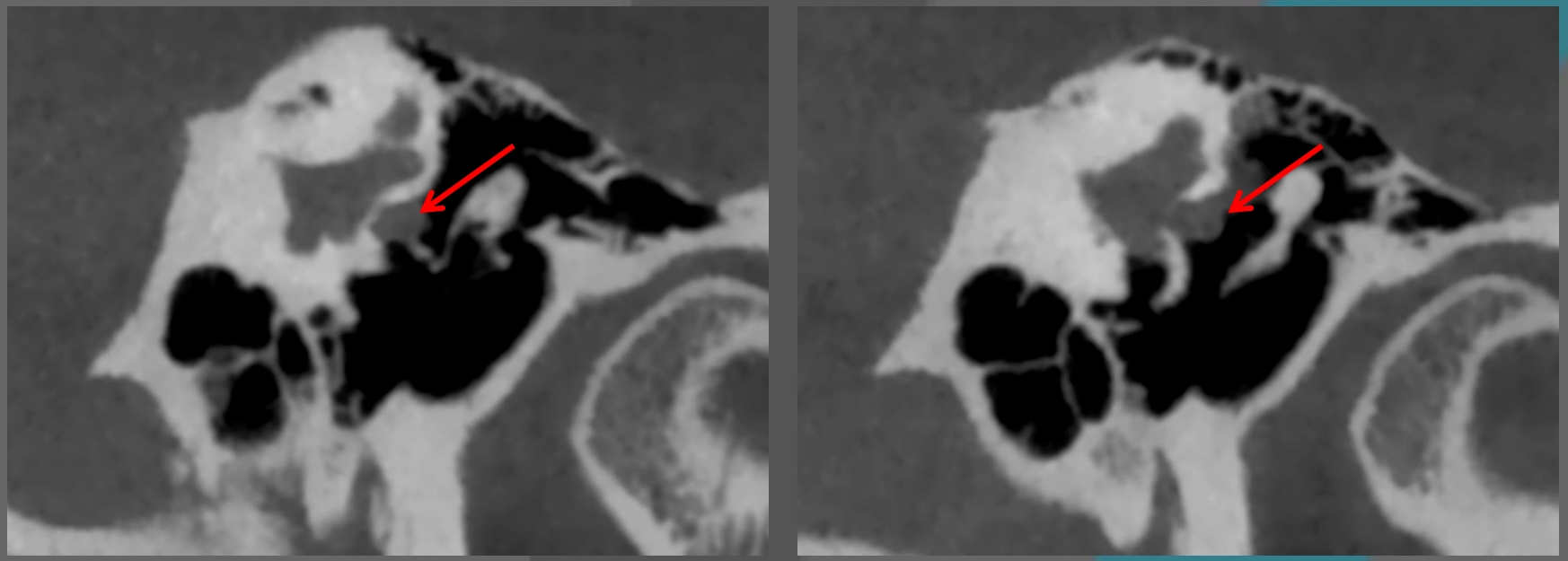

Izquierdo

INSTITUTS GUIRADO

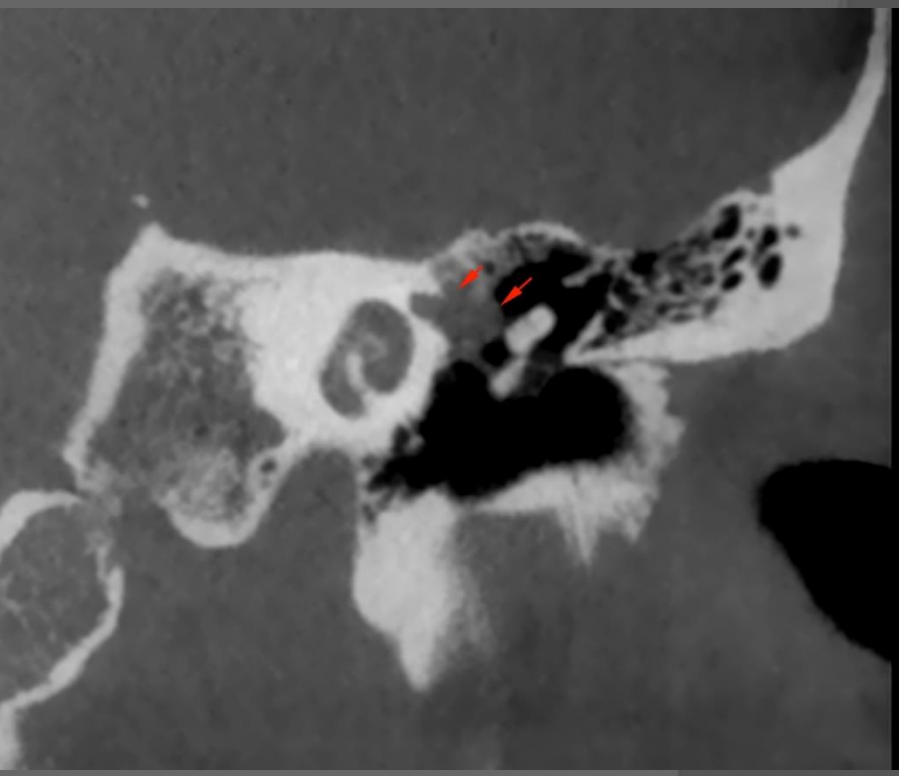

Coronal

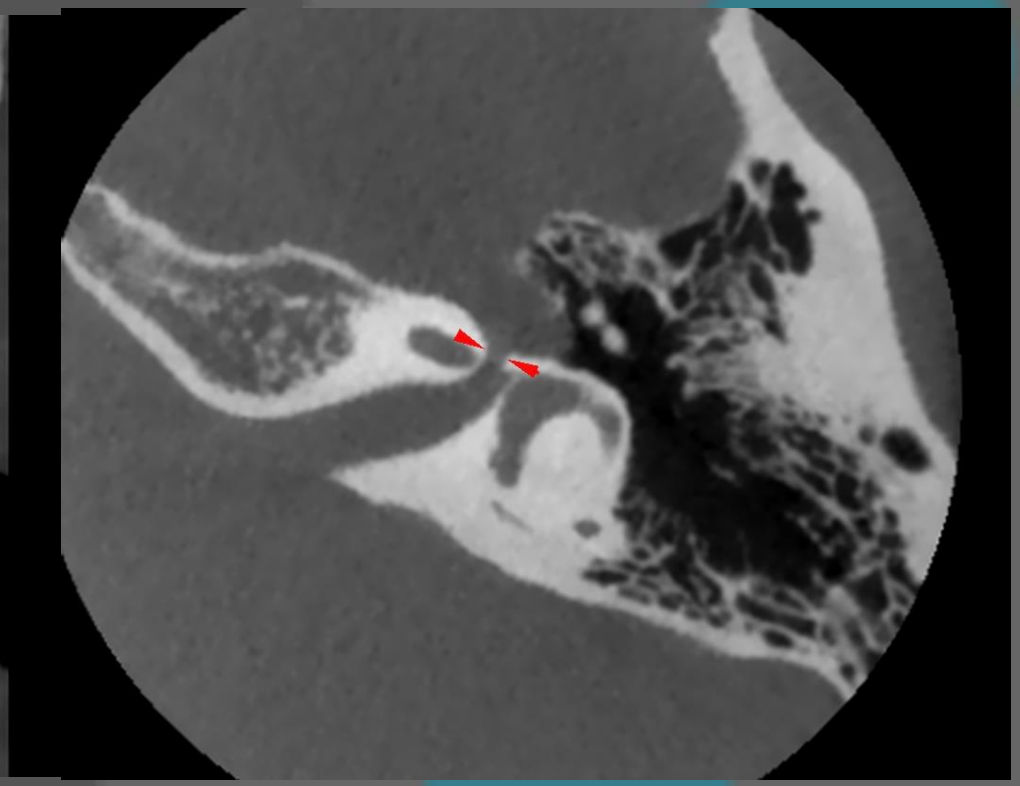

Axial

Izquierdo

INSTITUTS GUIRADO

1. Saito H, Baxter A. Undiagnosed intratemporal facial nerve neurilemomas. Arch Otolaryngol 1972; 95: 415–9. Google Scholar CrossRef, Medline
2. Pillsbury HCIII, Jones ROJr. Surgery for facial nerve neuroma. In: Wiet RJ, Causse J-B, eds. Ear and skull base. Philadelphia, Pa: BC Decker, 1986: 179–83. (Complications in otolaryngology—head and neck surgery; vol 1.). Google Scholar
3. Pulec JL. Symposium on ear surgery. II. Facial nerve neuroma. Laryngoscope 1972; 82: 1160–76. Google Scholar Medline
4. Inoue Y, Tabuchi T, Hakuba A, . Facial nerve neuromas: CT findings. J Comput Assist Tomogr 1987; 11: 942–7. Google Scholar Medline
5. Lipkin AF, Coker NJ, Jenkins HA, Alford BR. Intracranial and intratemporal facial neuroma. Otolaryngol Head Neck Surg 1987; 96: 71–9. Google Scholar Abstract
6. Conley J, Janecka I. Schwann cell tumors of the facial nerve. Laryngoscope 1974; 84: 958–62. Google Scholar Medline
7. Jackson CG, Glasscock MEIII, Hughes G, Sismanis A. Facial paralysis of neoplastic origin: Diagnosis and management. Laryngoscope 1980; 90: 1581–95. Google Scholar Medline
8. O'Donoghue GM, Brackmann DE, House JW, Jackler RK. Neuromas of the facial nerve. Am J Otol 1989; 10: 49–54. Google Scholar Medline
9. Parnes LS, Lee DH, Peerless SJ. Magnetic resonance imaging of facial nerve neuromas. Laryngoscope 1991; 101: 31–5. Google Scholar CrossRef, Medline