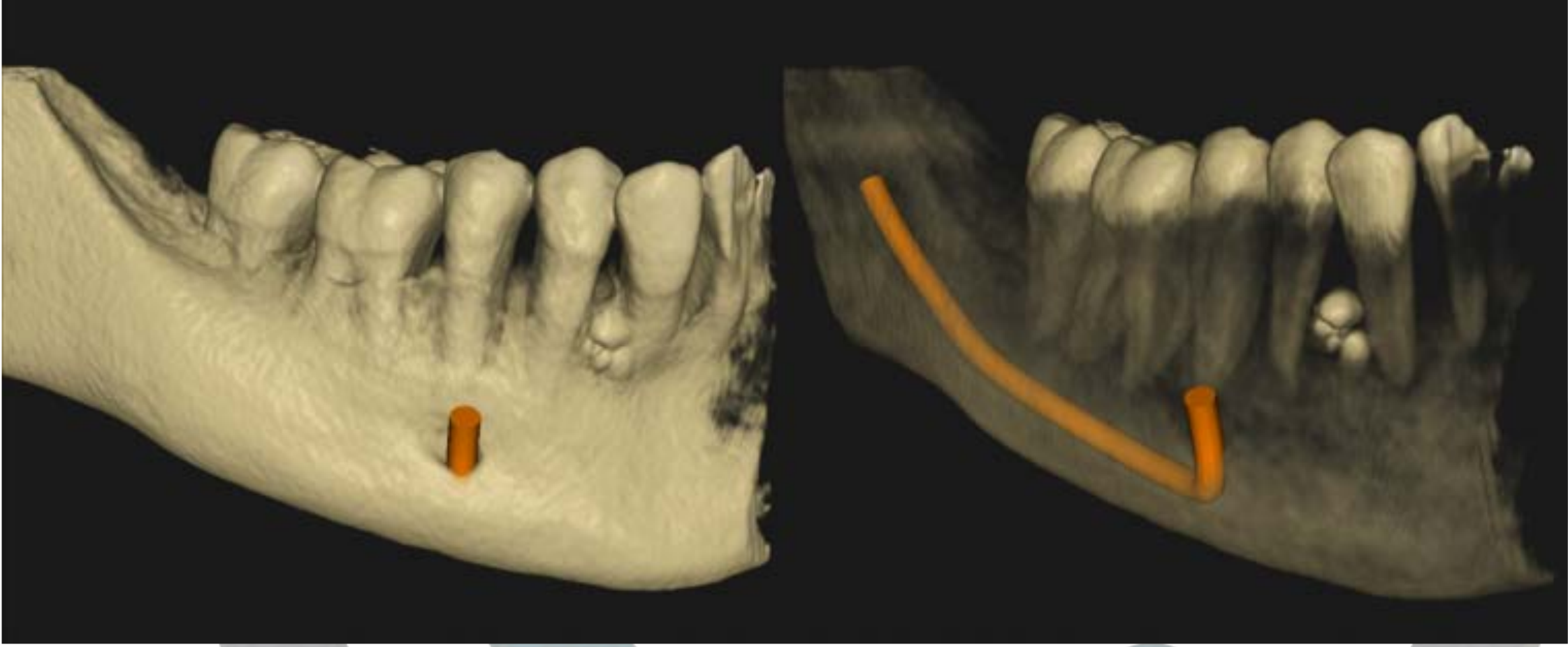
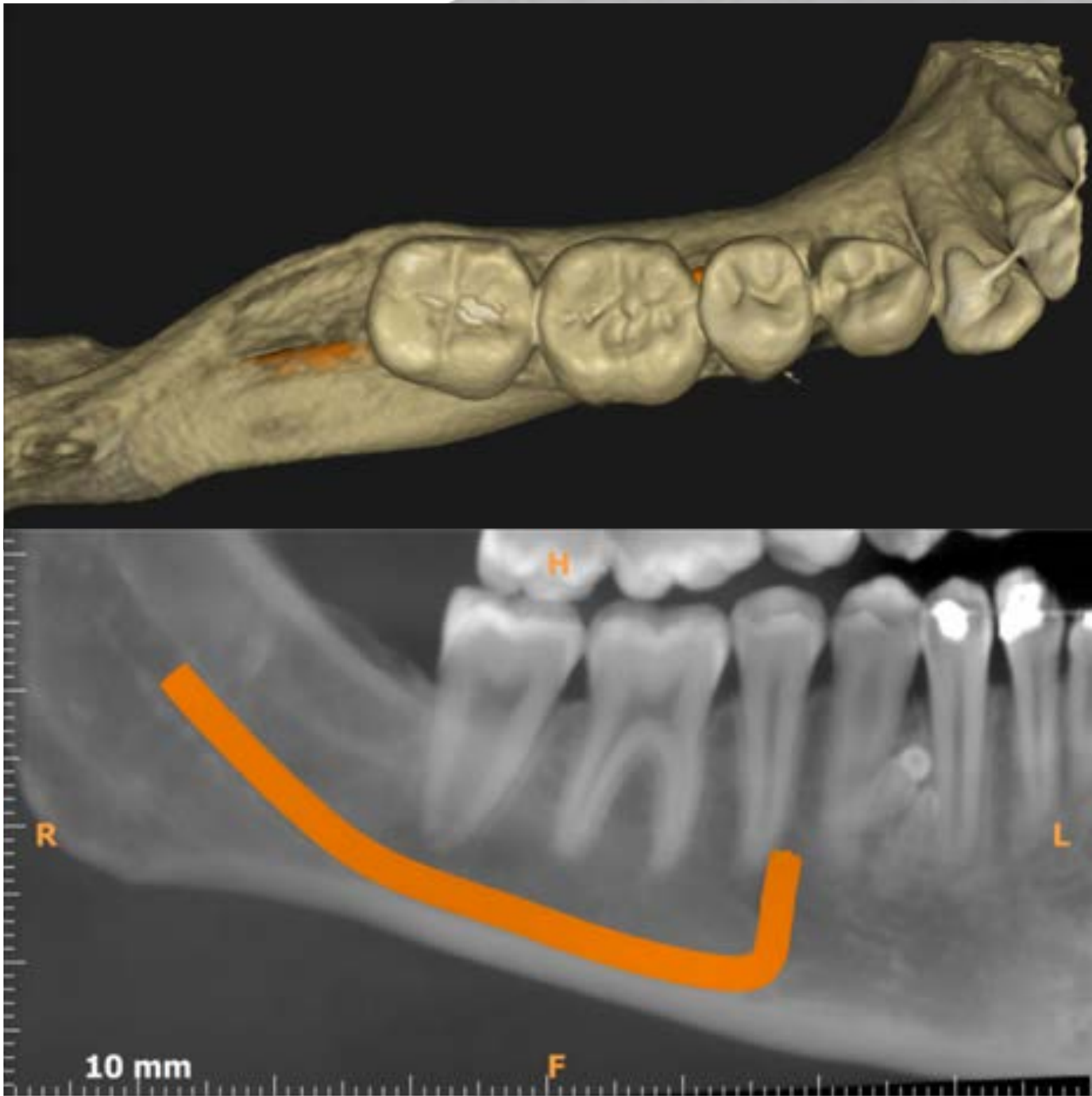
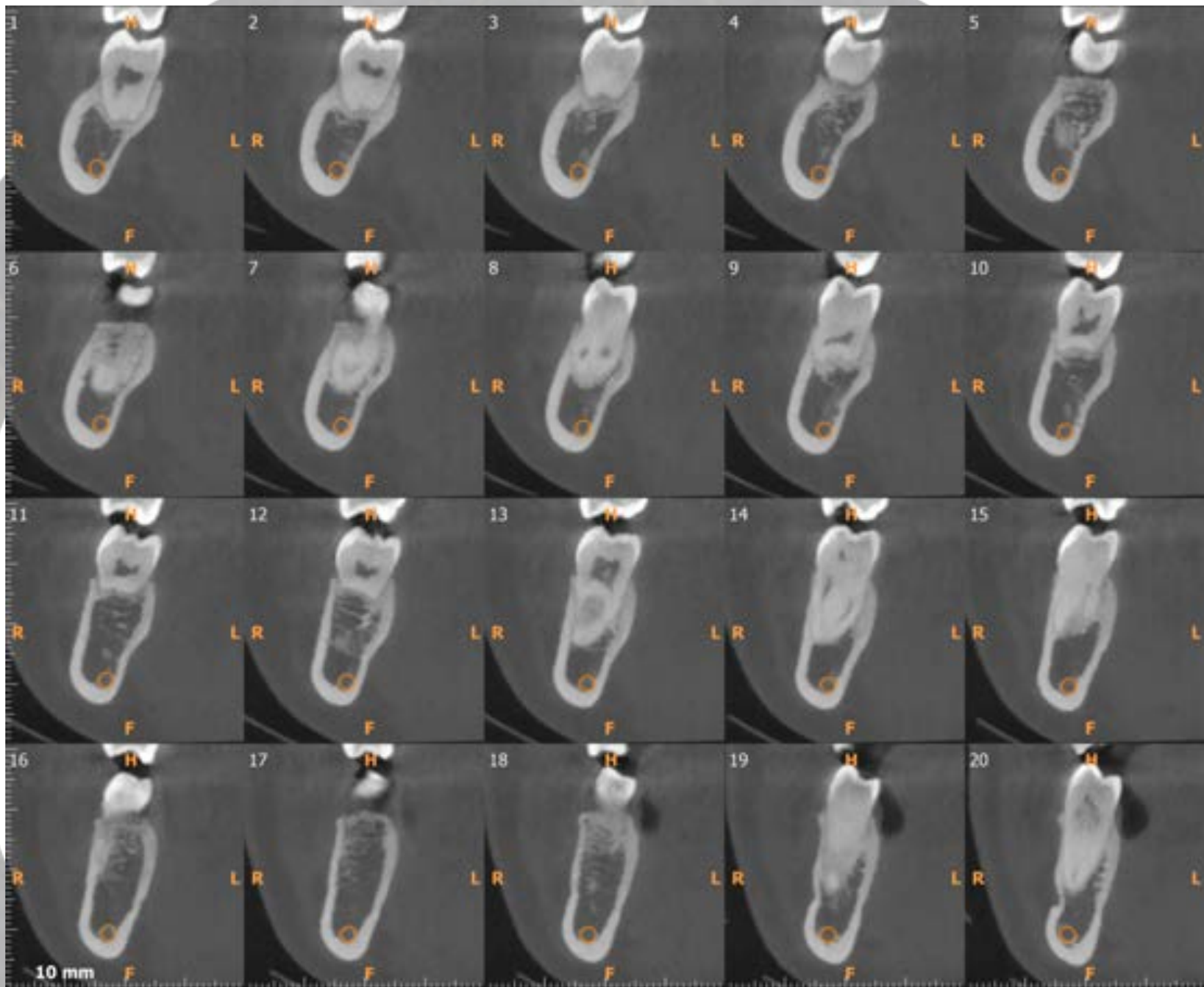
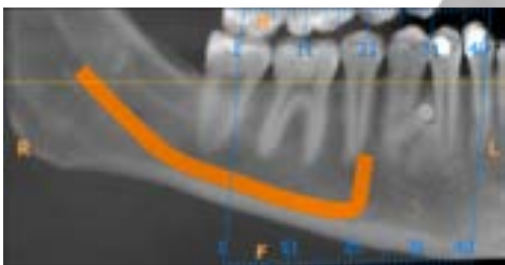
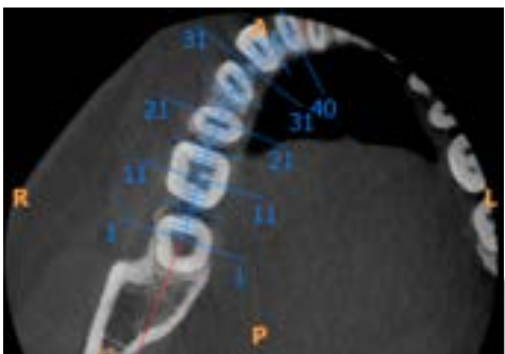
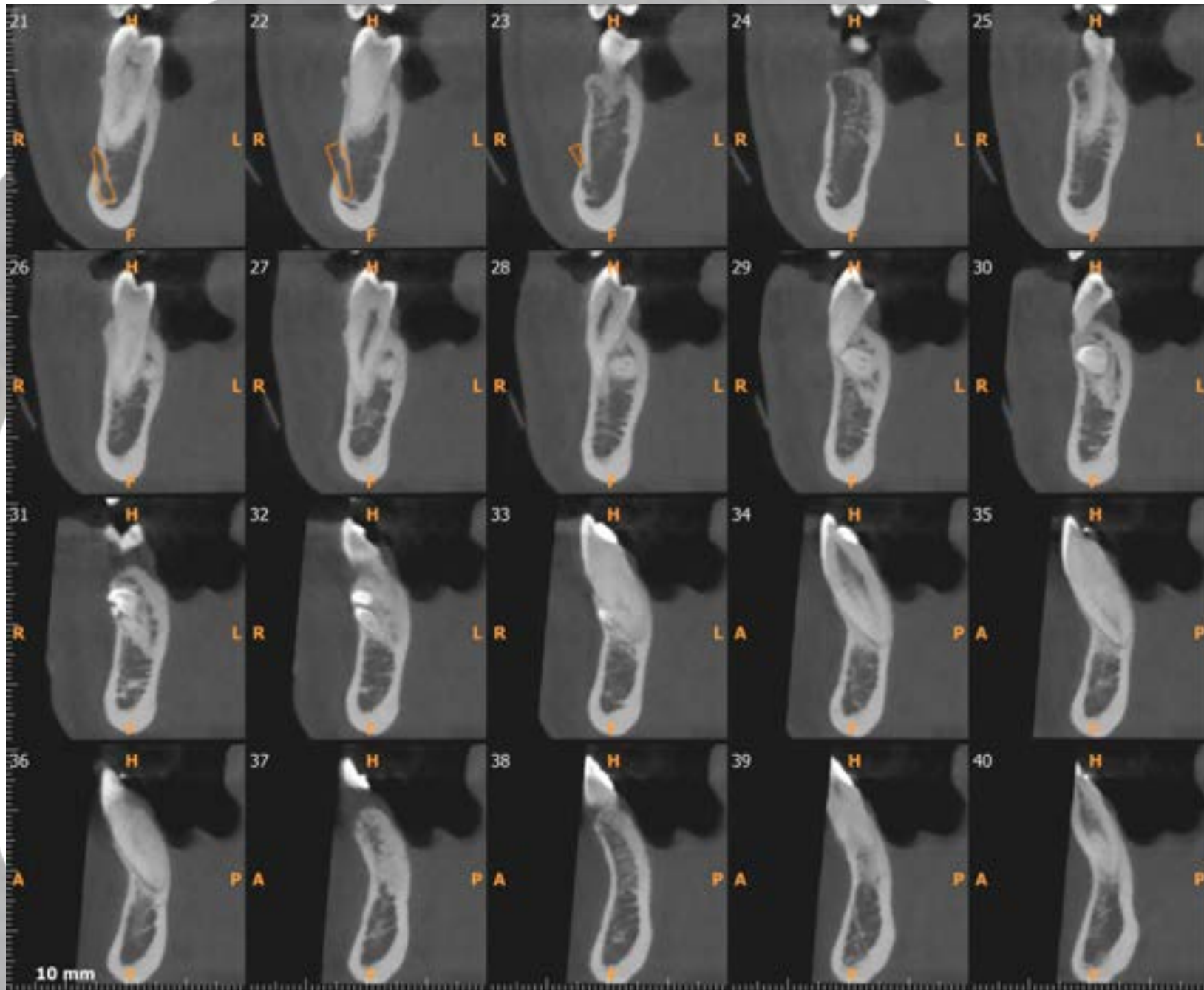
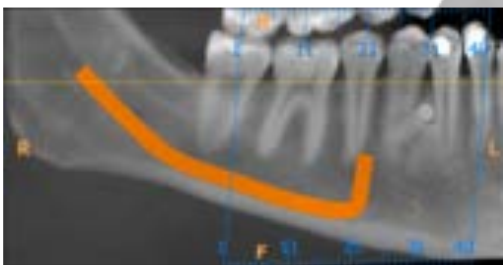
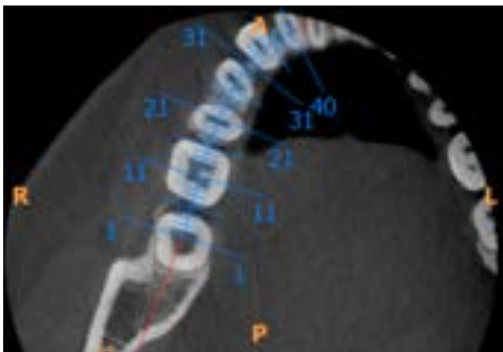


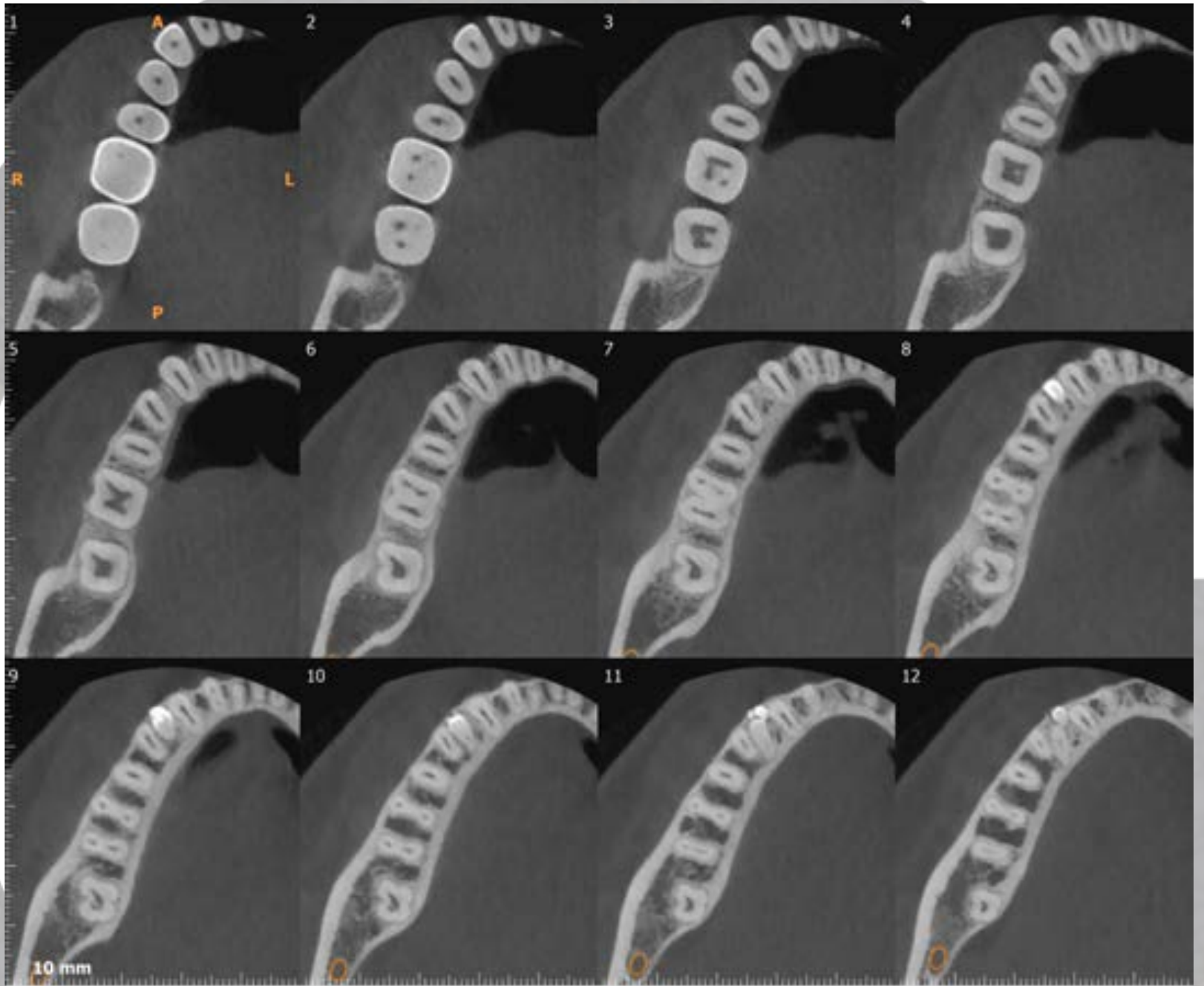
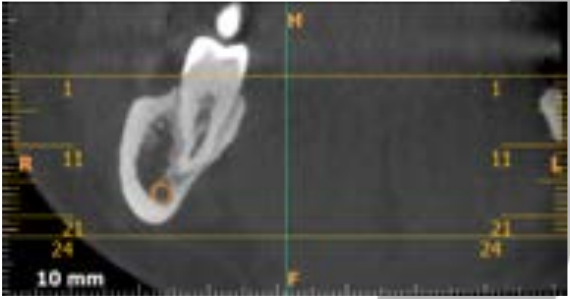
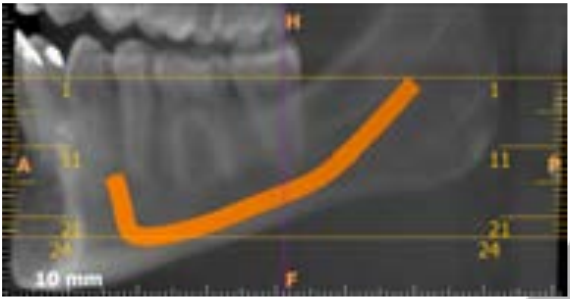
Caso Clínico
Odontoma compuesto
Dra. Araceli Martínez Miravé
Barcelona, Febrero 2019





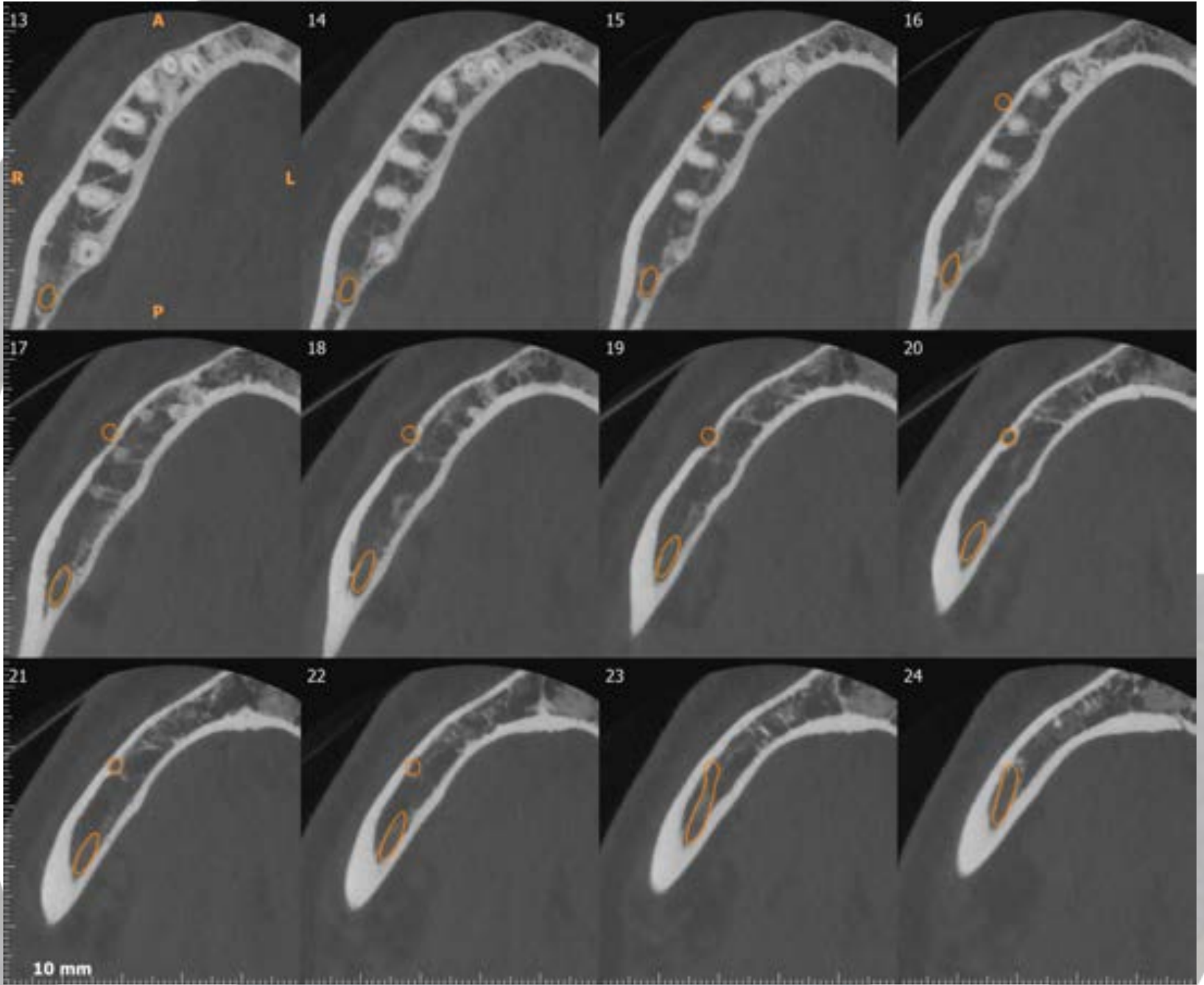
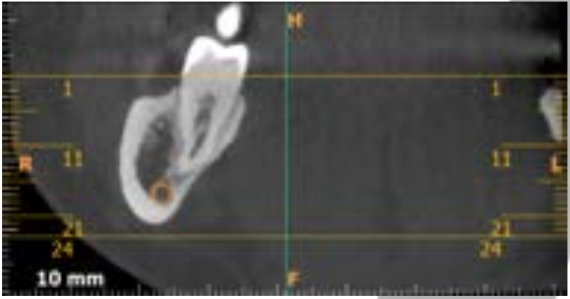
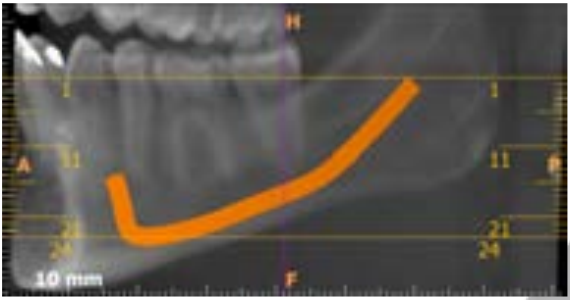


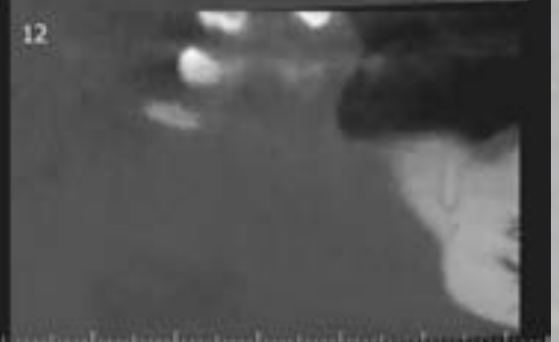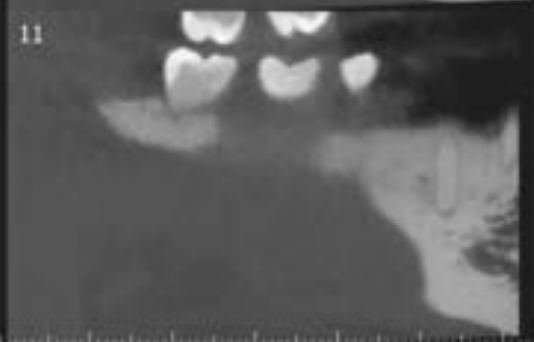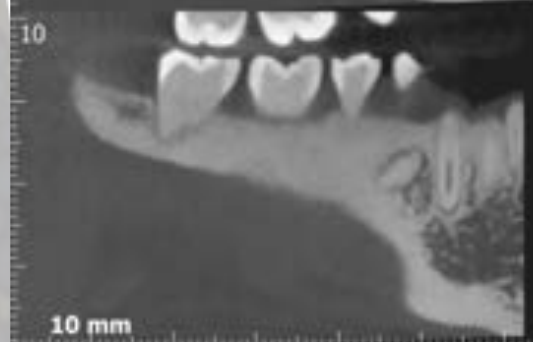
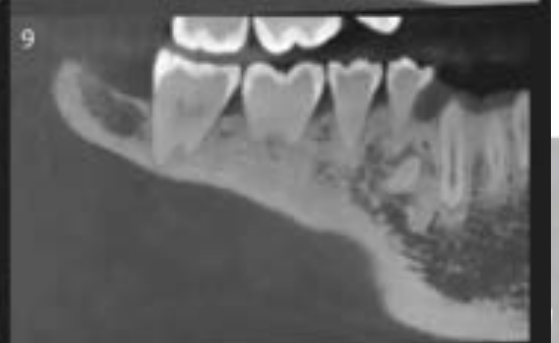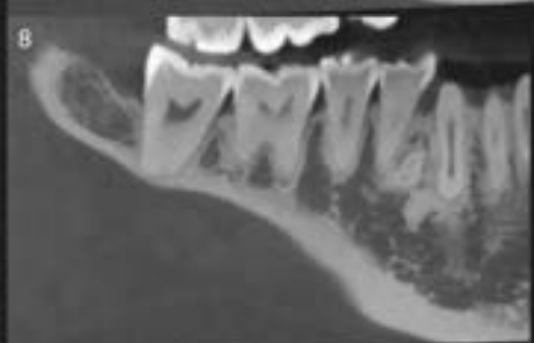
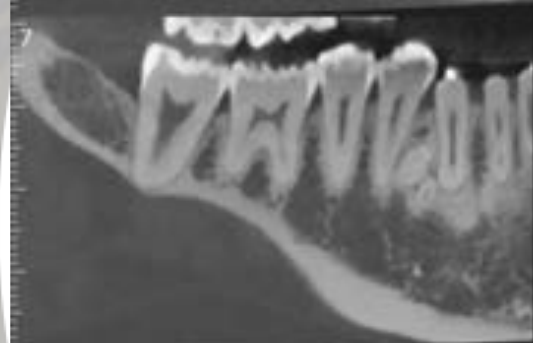
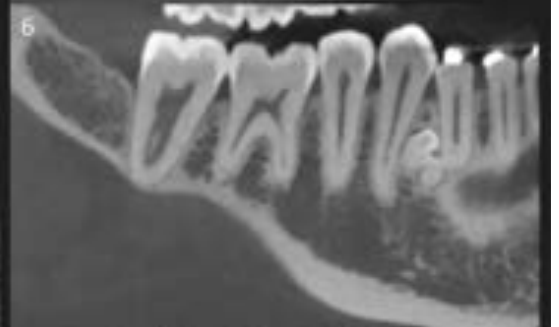
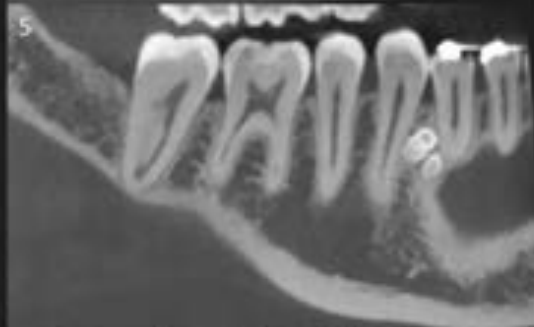
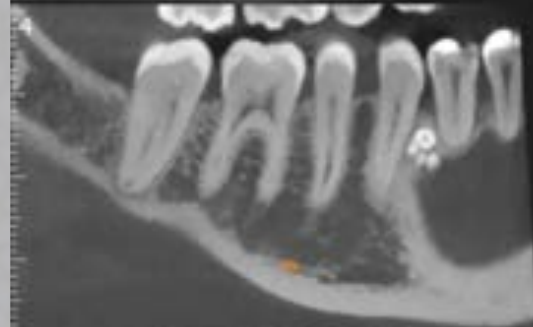
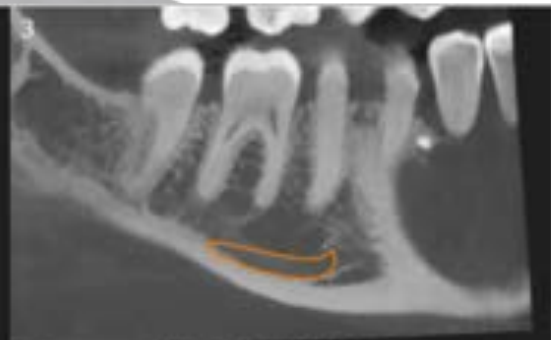
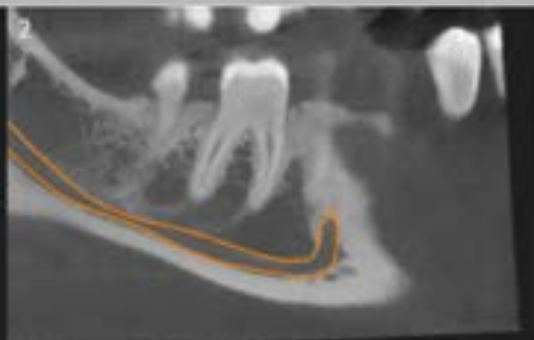
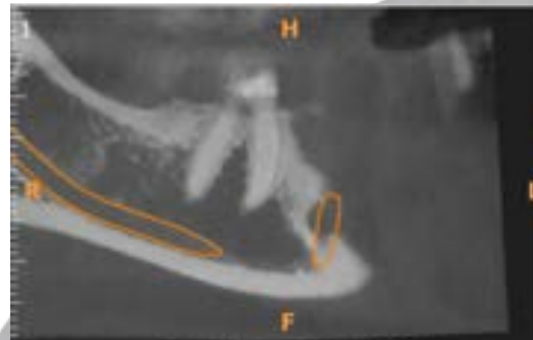
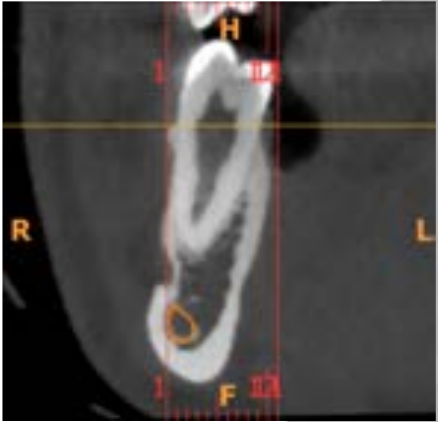
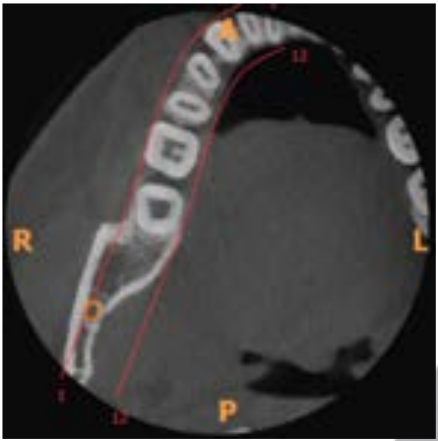






INSTITUTS GURADO





Conclusiones

En el sector apical del premolar 44 y del canino 43, por lingual de la raíz del premolar y por vestibular de la raíz del canino, observamos presencia de dentículos microdónticos, compatibles con odontoma compuesto (cortes ortorradales 26-33, axiales 8-13 y panorámicos 3-10). No se observa contacto ni proximidad de la lesión con el conducto dentario ni con el conducto mentoniano.